

CLINICAL PRACTICE

Caren G. Solomon, M.D., M.P.H., *Editor*

Diverticulitis

Tonia M. Young-Fadok, B.M., B.Ch.

This Journal feature begins with a case vignette highlighting a common clinical problem. Evidence supporting various strategies is then presented, followed by a review of formal guidelines, when they exist. The article ends with the author's clinical recommendations.

An otherwise healthy 57-year-old man presents with a 48-hour history of pain in the left lower quadrant. He has had three previous episodes of sigmoid diverticulitis that were confirmed by computed tomographic (CT) scan and treated nonsurgically. He has localized tenderness in the left lower quadrant. The body temperature is 101.8°F (38.8°C), the heart rate 110 beats per minute, and the white-cell count 15,600 per cubic millimeter. A CT scan of the abdomen and pelvis with oral and intravenous contrast material shows microperforation of the middle portion of the sigmoid colon, air bubbles in the adjacent colonic mesentery, thickening of the sigmoid wall, and pericolonic fat stranding, without free fluid. How would you manage this patient's condition?

THE CLINICAL PROBLEM

COLONIC DIVERTICULITIS IS AN INFLAMMATORY PROCESS THAT MOST commonly affects the sigmoid colon. A colonic diverticulum is a pouchlike protrusion in which mucosa and submucosa herniate through the muscle layer at points of weakness where blood vessels traverse the colon wall (Fig. 1). The term diverticulosis describes asymptomatic diverticula, whereas diverticulitis indicates diverticula associated with inflammation and can be either complicated (i.e., associated with abscess, fistula, stricture, or perforation and peritonitis) or uncomplicated. All manifestations are covered by the term diverticular disease.

Diverticular disease is the eighth-most-frequent outpatient gastrointestinal diagnosis in the United States, with 2.7 million associated health care visits annually.¹ The economic burden is high²: in a study of data from the National Inpatient Sample, 216,000 hospital admissions for diverticulitis in 2012 were found to cost \$2.2 billion.¹

The prevalence of diverticulosis has seemingly increased over the past century: in contrast to autopsy studies in the early 1900s that suggested prevalences of 2 to 10%, more recent reviews, based largely on administrative data, indicate that the prevalence ranges from 5% among patients younger than 40 years to 50% among patients older than 60 years.³ Rates of diverticulitis have also risen. In a population in the U.S. Midwest, the incidence of diverticulitis rose by more than 60%, from 115 cases per 100,000 person-years in the period from 1980 through 1989 to 188 per 100,000 in the period from 2000 through 2007, and the increase was greater among younger people.⁴

According to an analysis of data from the National Inpatient Sample,⁵ between 1998 and 2005, the rates of hospital admission for acute diverticulitis increased by

From the Division of Colon and Rectal Surgery, Mayo Clinic, Phoenix, AZ. Address reprint requests to Dr. Young-Fadok at the Division of Colon and Rectal Surgery, Mayo Clinic, 5777 E. Mayo Blvd., Phoenix, AZ 85054, or at youngfadok.tonia@mayo.edu.

This article was updated on January 31, 2019, at NEJM.org.

N Engl J Med 2018;379:1635-42.

DOI: 10.1056/NEJMc1800468

Copyright © 2018 Massachusetts Medical Society.



An audio version of this article is available at NEJM.org

KEY CLINICAL POINTS

DIVERTICULITIS

- Rates of diverticulitis are increasing in association with increasing rates of obesity.
- Evidence does not support the idea that seeds, nuts, and popcorn cause diverticulitis.
- Antibiotic agents are routinely used for outpatient management of diverticulitis in the United States, although limited data from randomized trials have called into question their role in this context.
- Patients who have diverticulitis that is successfully managed medically in the outpatient or inpatient setting are at low risk for undergoing an emergency colostomy in the future.
- The severity of recurrent episodes of diverticulitis is generally similar to that of the initial episode.
- When elective surgery is indicated, a laparoscopic approach results in better patient outcomes and lower health care costs than open surgery.
- Sigmoid resection with colostomy creation remains the safest and most widely used surgical procedure for perforated diverticulitis.

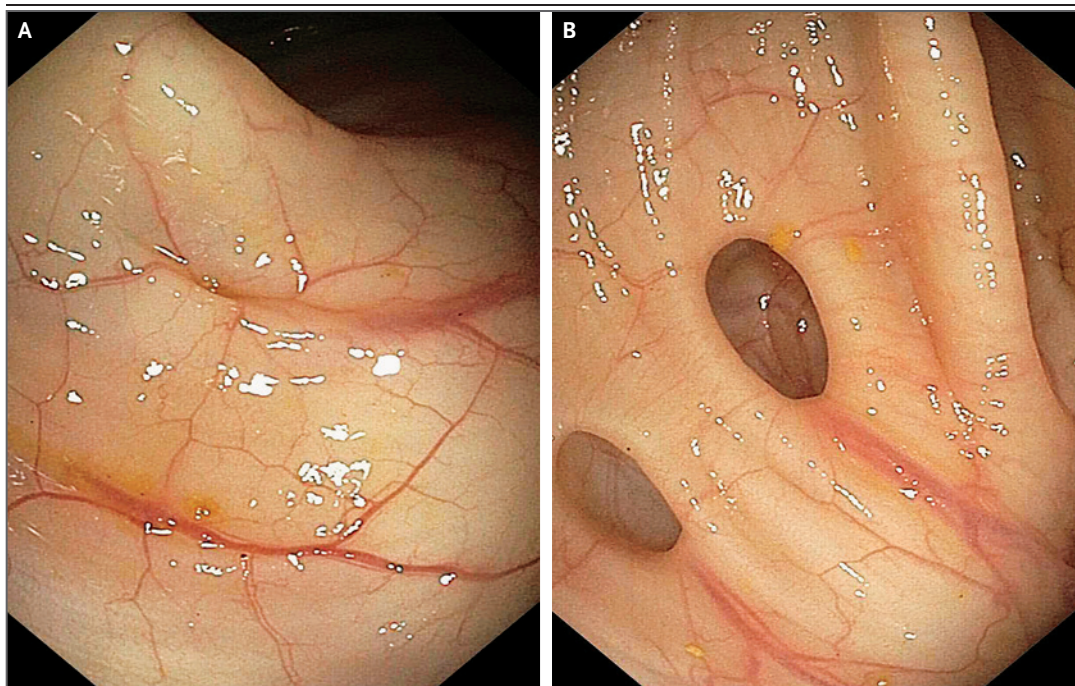


Figure 1. Colonoscopic View of an Incipient Diverticulum (Panel A) and Two Diverticula Associated with a Blood Vessel (Panel B).

26% and the rates of elective surgery for this condition increased by 38%. During that period, the mean age of patients hospitalized for acute diverticulitis decreased from 64.6 to 61.8 years.

Risk factors for diverticulitis include smoking,⁶ the use of nonsteroidal antiinflammatory drugs,⁷ and physical inactivity and obesity.⁸ Diets low in fiber^{9,10} and high in refined carbohydrates¹¹ and red meat¹² have also been associated with an increased risk of diverticulosis or diverticulitis.

The pathophysiology of diverticulosis and di-

verticulitis is uncertain, but it may involve altered gut motility and intraluminal pressure.¹³ One theory about diverticulitis postulates that the narrow neck of the diverticulum leads to bacterial overgrowth and tissue ischemia,¹⁴ but colonoscopic images do not show narrow necks (Fig. 1B). Alternatively, stool particles may accumulate in diverticula, become inspissated and hardened, and erode through the diverticular wall. If a diverticulum perforates freely into the abdominal cavity, diffuse peritonitis results,

whereas diverticula covered by mesentery are contained, creating a phlegmon or abscess, as well as localized peritoneal signs. Adjacent organs (e.g., the bladder and small bowel) may be drawn into the inflammatory process, resulting in fistula formation.

DIAGNOSIS AND EVALUATION

Diverticulitis typically manifests as pain in the left lower quadrant, fever, and leukocytosis. In patients with a redundant sigmoid colon and in Asian patients, pain is more often in the right lower quadrant or suprapubic area. Altered bowel habits (diarrhea or constipation) and pelvic pressure may occur.

Multislice CT imaging with intravenous and luminal contrast material has excellent sensitivity and specificity for the detection of diverticulitis (98% and 99%, respectively)^{15,16} and is the preferred test for diagnosis. CT should generally be performed for all first episodes and for subsequent episodes that are treated with percutaneous drainage or that contribute to a decision for surgical intervention.

Findings consistent with diverticulitis on CT include thickening of the colonic wall, pericolic fat stranding (indicating edema or inflammation), abscesses, localized air bubbles, and free air or fluid. A “microperforation” is a radiologic diagnosis reflecting localized perforation and inflammation (Fig. 2A). Free perforation is a surgical diagnosis made on the basis of sepsis and diffuse peritonitis — that is, an acute abdomen. The combination of CT findings (thickening of the colonic wall plus the presence of a complication) and an assessment on an overall scale of the severity of CT findings also predicts the risk of recurrence.¹⁷

CLASSIFICATION

Diverticulitis is classified as simple (uncomplicated) or complicated. Complicated diverticulitis refers to abscess, fistula, stricture, or free perforation, and simple diverticulitis describes inflammation without these features.

This classification does not predict severity or the need for surgery. Simple diverticulitis does not necessarily mean that surgical intervention will not be indicated (e.g., a microperforation may not become “walled off” in an immunosuppressed patient), and complicated diverticulitis

may not require surgery (e.g., treatment with antibiotic agents may be sufficient for a small abscess that is not amenable to drainage).

The Hinchey staging system classifies abscesses and free perforation (Fig. 2A and 2B). Its clinical utility is limited, but it is helpful for the classification of severity and homogeneity in

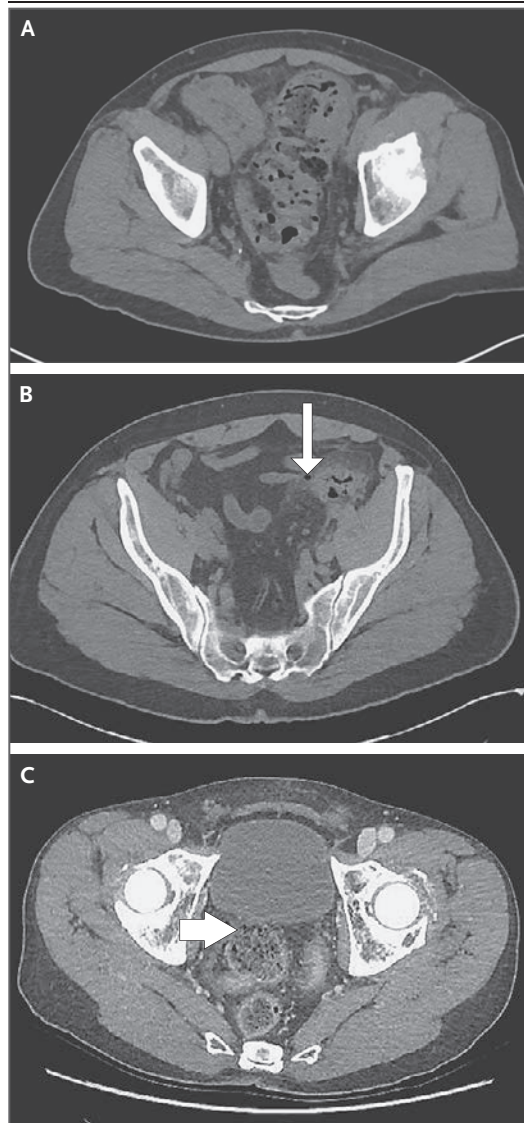


Figure 2. CT Images of the Colon in Patients with Diverticulitis.

Panel A shows uncomplicated diverticulitis with pericolic fat stranding. Panel B shows Hinchey stage I diverticulitis, with a small pericolic abscess and a bubble of extraluminal air (arrow). Panel C shows Hinchey stage IV diverticulitis with feculent peritonitis and a defect in the integrity of the colon wall (arrow).

clinical trials. Stage I disease is characterized by small pericolic or mesenteric abscesses. In stage II disease, the abscess is larger but is confined to the pelvis. Stage III disease indicates purulent peritonitis, and stage IV disease indicates fecal peritonitis (Fig. 2C). Higher stage numbers are associated with higher morbidity and mortality.¹⁸

After the specific manifestations of diverticulitis and the severity of disease are determined, the following issues need to be addressed: whether the patient needs to undergo surgery immediately (i.e., whether emergency intervention is indicated); if not, whether surgery will be needed during the hospital stay (i.e., whether urgent intervention is indicated); and, if not, whether the patient would benefit from elective surgery.

EMERGENCY INTERVENTION

Emergency surgery is indicated for sepsis or peritonitis, and urgent surgery is indicated if the patient's condition fails to improve despite medical therapy or percutaneous drainage. Free perforation causes sepsis and peritonitis, with severe diffuse abdominal pain, fever, tachycardia, and leukocytosis. A CT scan should be obtained in hemodynamically stable patients in order to localize perforation and rule out other diagnoses.

Emergency surgical intervention may be laparoscopic or open. Potential contraindications to a laparoscopic approach include hemodynamic instability, suspected feculent peritonitis, distended abdomen, obesity, and known extensive adhesions, as well as a lack of laparoscopic experience on the part of the surgeon. Commonly, sigmoid resection is performed, removing the perforated segment and leaving a rectal stump and end colostomy (Hartmann procedure). Because more than 30% of these procedures result in a permanent colostomy, two alternative approaches that might reduce this risk have been proposed — laparoscopic lavage and resection with primary anastomosis.

After early uncontrolled studies reported good outcomes with laparoscopic lavage,¹⁹ the technique was rapidly disseminated, reflecting its ease and simplicity as compared with emergency resection. Subsequent randomized trials comparing lavage with emergency resection, however, yielded inconsistent results. One trial was prematurely halted because of a higher rate of complications with lavage than with resection,²⁰ another showed a shorter hospital stay with lavage

but similar morbidity in the two groups,²¹ and a third reported more unplanned reoperations with lavage but lower stoma rates.²² Laparoscopic lavage of perforated diverticulitis remains controversial and should not be performed outside a randomized trial.

Resection and primary anastomosis with loop ileostomy require two operations (resection of the perforated sigmoid, anastomosis, and diverting ileostomy first, followed by closure of the ileostomy). However, loop ileostomy is more likely to be reversed than end colostomy, and the reversal requires reentry into an abdominal cavity that may have extensive adhesions.^{23,24} The procedure has not been widely adopted. A review of the National Inpatient Sample from 1998 through 2011 showed that more than 90% of patients had end colostomy and that patients with primary anastomosis and diversion had higher morbidity and mortality.²⁵ A randomized trial comparing these approaches showed similar mortality in the two groups but higher rates of stoma reversal in the primary-anastomosis group.²⁶

Overall, 14 to 20% of patients with acute diverticulitis undergo emergency and semiurgent surgical procedures during the same hospitalization.^{5,27} Slightly more than half of these patients receive a colostomy,⁵ and 30% of these will be permanent. Reversal of the stoma depends on coexisting conditions and surgical expertise; not all surgeons who create stomas can reverse them.

LOCALIZED PERFORATION — UNCOMPLICATED DIVERTICULITIS

Simple diverticulitis reflects localized inflammation and accounts for approximately 75% of cases of diverticulitis. In the absence of high fever, clinically significant laboratory or radiologic abnormalities, or immunosuppression, the condition can be managed on an outpatient basis. Randomized trials have shown no significant benefit of intravenous over oral antibiotics.^{28,29} Moreover, two trials evaluating routine antibiotic treatment as compared with no antibiotic treatment have shown no significant difference in outcomes.³⁰⁻³² Despite the lack of data to confirm benefits, oral antibiotics are routinely prescribed in the United States. Common outpatient regimens are oral ciprofloxacin (500 mg twice a day) plus metronidazole (500 mg three times a day), or amoxicillin-clavulanate (875 mg twice

a day), for 7 to 10 days. Traditionally, an oral diet of clear liquids is advocated until pain resolves.

Inpatient management is indicated for high fever (body temperature $>101.5^{\circ}\text{F}$ [$>38.6^{\circ}\text{C}$]), leukocytosis, complicated disease on CT, immunosuppression, serious coexisting conditions, a lack of home support, a need for pain control, or an inability to receive oral intake. Standard management includes bowel rest, pain control, and antibiotics, usually administered intravenously because of an inability to receive oral intake. Antibiotic therapy should cover gram-negative and anaerobic bacteria; typical regimens include ceftriaxone plus metronidazole, single-agent therapy with a β -lactam or β -lactam/ β -lactamase inhibitor combination, or meropenem.

Symptoms typically improve within 2 to 3 days after the initiation of treatment, at which time the diet is commonly advanced to clear liquids and then to a low-residue diet, although data from randomized trials to guide dietary management are limited. Deterioration or a lack of improvement should prompt repeat imaging. In the absence of a treatable cause of a poor response (i.e., a drainable abscess), surgical intervention is indicated. Patients with coexisting conditions that may mask the clinical presentation (e.g., immunosuppression or dementia) are at higher risk for deterioration.

Abscesses smaller than 3 to 4 cm in diameter are not amenable to percutaneous drainage and are treated with antibiotics. Larger abscesses are less common and may be managed by percutaneous drainage on initial presentation or if medical management fails; failure of medical management alone is more likely in patients with abscesses larger than 5 cm in diameter.³³ Whereas some studies have reported that up to 70% of patients with abscesses ultimately undergo surgery, others have shown that fewer than half the patients had recurrent diverticulitis and that recurrences were effectively managed nonsurgically.^{34,35}

Before colonoscopy became widely performed (and covered by insurance) for screening purposes, this procedure was routinely recommended 6 to 8 weeks after resolution of an acute episode of diverticulitis, to rule out colon cancer. With current CT imaging, confusion between uncomplicated diverticulitis and cancer is rare; in a review, cancer was found in only 5 of 1497 patients who had CT evidence of uncomplicated

diverticulitis.³⁶ Colonoscopy is currently recommended after the resolution of acute diverticulitis if a high-quality examination has not been performed recently³⁷; although “recently” is not defined, colonoscopy should be considered if more than 2 to 3 years have elapsed since the last examination.

RECURRENCE

The risk of recurrence after an episode of diverticulitis varies widely among studies and depends on the study cohort (inpatient or population-based)^{4,35} and the definition of recurrence (readmission or antibiotic treatment).^{4,35} A systematic review showed recurrence rates of 10 to 35% after a first episode of uncomplicated diverticulitis.²⁷ After two episodes, the risk of recurrence was higher, but the severity of the recurrent episodes was similar to that of earlier episodes.^{27,38} Free perforation is more likely in patients who have no history of diverticulitis than in those with a previous episode (25% vs. 12%).^{27,39}

Limited and inconsistent evidence (from small randomized trials and a case-control study) has suggested that a high-fiber diet after acute diverticulitis may reduce the risk of recurrence.⁴⁰ Patients are often advised to avoid popcorn, seeds, and nuts after an episode of diverticulitis, although a prospective cohort study of male health professionals showed no association between intake of corn, seeds, and nuts and the risk of diverticulitis over 18 years of follow-up.⁴¹

ELECTIVE SURGERY FOR RECURRENT UNCOMPLICATED DIVERTICULITIS

In most patients who have diverticulitis-associated perforation of the bowel, the perforation occurs during their first attack.⁴² The decision to pursue elective surgery after an episode of diverticulitis that was treated nonsurgically is challenging. Many patients will not have another attack after an initial episode of uncomplicated diverticulitis,²⁷ and only 3 to 5% have complicated recurrence after uncomplicated diverticulitis.⁴ Among patients who undergo segmental resection, recurrent diverticulitis in the remaining colon after resection is uncommon (5% of cases) and leads to repeat surgery only in rare cases (0.4% of cases).⁴³

In the DIRECT trial, patients with three or more proven attacks of diverticulitis or persistent symptoms after one confirmed attack were

randomly assigned to undergo surgery or receive conservative management.⁴⁴ The trial was stopped early by the data and safety monitoring board owing to slow recruitment (only 109 patients were recruited over a period of 4 years in 24 centers). The Gastrointestinal Quality of Life Index score at 6 months (the primary outcome) was significantly better in the surgery group, and severe adverse events appeared to be less common overall with surgery than with conservative management. However, the rate of anastomotic leak in the surgery group (in the form of abscess or a more serious condition, peritonitis) was high, at 15%.

Whereas older guidelines from the American Society of Colon and Rectal Surgeons (ASCRS) recommended surgery after two attacks of uncomplicated diverticulitis, current guidelines⁴⁵ recommend that decisions regarding elective surgery should not be driven by the number of episodes but rather should be individualized. A decision-analysis model suggests that elective resection after a fourth episode is not associated with a higher risk of death or colostomy formation than earlier resection.⁴⁶ Considerations include the severity and frequency of attacks, coexisting conditions, patient preference (or aversion) regarding surgery, and quality of life. It is helpful to compare the estimated risk of perforation from another attack (which is likely to be similar in severity to previous episodes) with the risk of surgical complications (estimated on the basis of coexisting conditions). Patients who have complicated diverticulitis with fistula or stricture may not require emergency surgery but may require elective surgical intervention. Patients with immunosuppression, collagen vascular disease, glucocorticoid use, malnutrition, or obesity are at increased risk for recurrence and perforation⁴⁷⁻⁴⁹ but also have increased surgical risks, and tailored decision making is necessary.⁴⁵

Elective surgery can be laparoscopic or open. Although a Cochrane review of three randomized trials comparing laparoscopic and open surgery for diverticulitis was inconclusive,⁵⁰ the quality of the available data was considered to be low, and a meta-analysis of 25 randomized trials comparing open and laparoscopic colon resection for any indication showed superior outcomes with laparoscopy (i.e., less pain, lower rates of hospitalization and complications, lower costs, and better quality of life).⁵¹

AREAS OF UNCERTAINTY

What we thought we knew is no longer what we know. The mainstay role of oral antibiotics for outpatient management of diverticulitis has been challenged. Data from large-scale studies will be required in order to achieve practice change with regard to the prescription of oral antibiotics. The role of antibiotics as compared with percutaneous drainage for medium-size abscesses (3 to 5 cm in diameter) requires further study.

Further investigation is necessary for an understanding of the pathogenesis of diverticulitis. A major area of uncertainty is when resection is indicated for recurrent disease to prevent future complications.

Given the data confirming the benefits of laparoscopic surgery over open resection,⁵¹ barriers to laparoscopy should be evaluated. However, clear indications for resection need to be better defined.

As the incidence of diverticulitis increases among patients who are becoming more obese and have additional coexisting conditions, the patients are less able to undergo resection safely to obviate the source of their symptoms, and alternative medications have been sought. Rifaximin (a poorly absorbed oral antibiotic) and mesalamine (an antiinflammatory agent that exerts topical effects) have been proposed as possible agents to reduce the recurrence of diverticulitis, but the available data do not suggest a substantive benefit.⁵²⁻⁵⁴ More data on medications that may reduce the need for surgical intervention are needed.

GUIDELINES

The ASCRS⁴⁵ and the American Gastroenterological Association³⁷ have published guidelines for the management of diverticulitis. The level of consistency between the sets of guidelines is exemplary, and the recommendations in this article are generally consistent with those in the guidelines, other than my emphasis on urgent bedside decision making.

CONCLUSIONS AND RECOMMENDATIONS

The patient described in the vignette has signs of systemic inflammatory response syndrome with

localized abdominal tenderness and uncomplicated diverticulitis on CT scan; the microperforation that was seen on CT is the localized inflammatory process around the causative diverticulum. He should be hospitalized, receive nothing by mouth, and be treated with intravenous fluids and broad-spectrum antibiotics; after the tenderness resolves, I would switch to oral antibiotics and advance his diet. If his condition does not improve or deteriorates over the next 24 to 48 hours, repeat CT is warranted and may show an

abscess amenable to percutaneous drainage. After resolution of this episode, if he has had a recent colonoscopy, another is not indicated unless there are suspicious findings on CT. On the basis of the number of attacks and increased severity, I would recommend surgical consultation for consideration of elective surgery after resolution of this acute episode.

No potential conflict of interest relevant to this article was reported.

Disclosure forms provided by the author are available with the full text of this article at NEJM.org.

REFERENCES

1. Peery AF, Crockett SD, Barritt AS, et al. Burden of gastrointestinal, liver, and pancreatic diseases in the United States. *Gastroenterology* 2015;149(7):1731-1741.e3.
2. Van Arendonk KJ, Tymitz KM, Gearhart SL, Stem M, Lidor AO. Outcomes and costs of elective surgery for diverticular disease: a comparison with other diseases requiring colectomy. *JAMA Surg* 2013;148:316-21.
3. Weizman AV, Nguyen GC. Diverticular disease: epidemiology and management. *Can J Gastroenterol* 2011;25:385-9.
4. Bharucha AE, Parthasarathy G, Ditah I, et al. Temporal trends in the incidence and natural history of diverticulitis: a population-based study. *Am J Gastroenterol* 2015;110:1589-96.
5. Etzioni DA, Mack TM, Beart RW Jr, Kaiser AM. Diverticulitis in the United States: 1998-2005: changing patterns of disease and treatment. *Ann Surg* 2009;249:210-7.
6. Hjern F, Wolk A, Håkansson N. Smoking and the risk of diverticular disease in women. *Br J Surg* 2011;98:997-1002.
7. Strate LL, Liu YL, Huang ES, Giovannucci EL, Chan AT. Use of aspirin or nonsteroidal anti-inflammatory drugs increases risk for diverticulitis and diverticular bleeding. *Gastroenterology* 2011;140:1427-33.
8. Hjern F, Wolk A, Håkansson N. Obesity, physical inactivity, and colonic diverticular disease requiring hospitalization in women: a prospective cohort study. *Am J Gastroenterol* 2012;107:296-302.
9. Painter NS, Burkitt DP. Diverticular disease of the colon, a 20th century problem. *Clin Gastroenterol* 1975;4:3-21.
10. Aldoori WH, Giovannucci EL, Rimm EB, Wing AL, Trichopoulos DV, Willett WC. A prospective study of diet and the risk of symptomatic diverticular disease in men. *Am J Clin Nutr* 1994;60:757-64.
11. Strate LL, Keeley BR, Cao Y, Wu K, Giovannucci EL, Chan AT. Western dietary pattern increases, and prudent dietary pattern decreases, risk of incident diverticulitis in a prospective cohort study. *Gastroenterology* 2017;152(5):1023-1030.e2.
12. Cao Y, Strate LL, Keeley BR, et al. Meat intake and risk of diverticulitis among men. *Gut* 2018;67:466-72.
13. Morris AM, Regenberg SE, Hardiman KM, Hendren S. Sigmoid diverticulitis: a systematic review. *JAMA* 2014;311:287-97.
14. Jacobs DO. Diverticulitis. *N Engl J Med* 2007;357:2057-66.
15. Laméris W, van Randen A, Bipat S, Bossuyt PM, Boermeester MA, Stoker J. Graded compression ultrasonography and computed tomography in acute colonic diverticulitis: meta-analysis of test accuracy. *Eur Radiol* 2008;18:2498-511.
16. Ambrosetti P, Jenny A, Becker C, Terrier TF, Morel P. Acute left colonic diverticulitis — compared performance of computed tomography and water-soluble contrast enema: prospective evaluation of 420 patients. *Dis Colon Rectum* 2000;43:1363-7.
17. Dickerson EC, Chong ST, Ellis JH, et al. Recurrence of colonic diverticulitis: identifying predictive CT findings — retrospective cohort study. *Radiology* 2017;285:850-8.
18. Schwesinger WH, Page CP, Gaskill HV III, et al. Operative management of diverticular emergencies: strategies and outcomes. *Arch Surg* 2000;135:558-62.
19. Cirocchi R, Trastulli S, Vettoretto N, et al. Laparoscopic peritoneal lavage: a definitive treatment for diverticular peritonitis or a “bridge” to elective laparoscopic sigmoidectomy? A systematic review. *Medicine (Baltimore)* 2015;94(1):e334.
20. Vennix S, Musters GD, Mulder IM, et al. Laparoscopic peritoneal lavage or sigmoidectomy for perforated diverticulitis with purulent peritonitis: a multicentre, parallel-group, randomised, open-label trial. *Lancet* 2015;386:1269-77.
21. Angenete E, Thornell A, Burcharth J, et al. Laparoscopic lavage is feasible and safe for the treatment of perforated diverticulitis with purulent peritonitis: the first results from the randomized controlled trial DILALA. *Ann Surg* 2016;263:117-22.
22. Schultz JK, Wallon C, Bleic L, et al. One-year results of the SCANDIV randomized clinical trial of laparoscopic lavage versus primary resection for acute perforated diverticulitis. *Br J Surg* 2017;104:1382-92.
23. Gawlick U, Nirula R. Resection and primary anastomosis with proximal diversion instead of Hartmann's: evolving the management of diverticulitis using NSQIP data. *J Trauma Acute Care Surg* 2012;72:807-14.
24. Tabbara M, Velmahos GC, Butt MU, et al. Missed opportunities for primary repair in complicated acute diverticulitis. *Surgery* 2010;148:919-24.
25. Cauley CE, Patel R, Bordeianou L. Use of primary anastomosis with diverting ileostomy in patients with acute diverticulitis requiring urgent operative intervention. *Dis Colon Rectum* 2018;61:586-92.
26. Bridoux V, Regimbeau JM, Ouassini M, et al. Hartmann's procedure or primary anastomosis for generalized peritonitis due to perforated diverticulitis: a prospective multicenter randomized trial (DIVERTI). *J Am Coll Surg* 2017;225:798-805.
27. Regenberg SE, Hardiman KM, Hendren S, Morris AM. Surgery for diverticulitis in the 21st century: a systematic review. *JAMA Surg* 2014;149:292-303.
28. Ribas Y, Bombardó J, Aguilar F, et al. Prospective randomized clinical trial assessing the efficacy of a short course of intravenously administered amoxicillin plus clavulanic acid followed by oral antibiotic in patients with uncomplicated acute diverticulitis. *Int J Colorectal Dis* 2010;25:1363-70.
29. Ridgway PF, Latif A, Shabbir J, et al. Randomized controlled trial of oral vs intravenous therapy for the clinically diagnosed acute uncomplicated diverticulitis. *Colorectal Dis* 2009;11:941-6.
30. Daniels L, Ünüç Ç, de Korte N, et al. Randomized clinical trial of observational versus antibiotic treatment for a first episode of CT-proven uncomplicated acute diverticulitis. *Br J Surg* 2017;104:52-61.
31. Chabok A, Pahlman L, Hjern F, Haapaniemi S, Smedh K. Randomized clinical trial of antibiotics in acute uncomplicated diverticulitis. *Br J Surg* 2012;99:532-9.

32. Shabanzadeh DM, Wille-Jørgensen P. Antibiotics for uncomplicated diverticulitis. *Cochrane Database Syst Rev* 2012;11:CD009092.
33. Ambrosetti P, Chautems R, Soravia C, Peiris-Waser N, Terrier F. Long-term outcome of mesocolic and pelvic diverticular abscesses of the left colon: a prospective study of 73 cases. *Dis Colon Rectum* 2005;48:787-91.
34. Gaertner WB, Willis DJ, Madoff RD, et al. Percutaneous drainage of colonic diverticular abscess: is colon resection necessary? *Dis Colon Rectum* 2013;56:622-6.
35. Broderick-Villa G, Burchette RJ, Collins JC, Abbas MA, Haigh PI. Hospitalization for acute diverticulitis does not mandate routine elective colectomy. *Arch Surg* 2005;140:576-81.
36. Sharma PV, Eglinton T, Hider P, Frieze F. Systematic review and meta-analysis of the role of routine colonic evaluation after radiologically confirmed acute diverticulitis. *Ann Surg* 2014;259:263-72.
37. Stollman N, Smalley W, Hirano I. American Gastroenterological Association Institute guideline on the management of acute diverticulitis. *Gastroenterology* 2015;149:1944-9.
38. Chapman JR, Dozois EJ, Wolff BG, Gullerud RE, Larson DR. Diverticulitis: a progressive disease? Do multiple recurrences predict less favorable outcomes? *Ann Surg* 2006;243:876-30.
39. Ritz JP, Lehmann KS, Frericks B, Stroux A, Buhr HJ, Holmer C. Outcome of patients with acute sigmoid diverticulitis: multivariate analysis of risk factors for free perforation. *Surgery* 2011;149:606-13.
40. Ünlü C, Daniels L, Vrouenraets BC, Boermeester MA. A systematic review of high-fibre dietary therapy in diverticular disease. *Int J Colorectal Dis* 2012;27:419-27.
41. Strate LL, Liu YL, Syngal S, Aldoori WH, Giovannucci EL. Nut, corn, and popcorn consumption and the incidence of diverticular disease. *JAMA* 2008;300:907-14.
42. Anaya DA, Flum DR. Risk of emergency colectomy and colostomy in patients with diverticular disease. *Arch Surg* 2005;140:681-5.
43. Thaler K, Baig MK, Berho M, et al. Determinants of recurrence after sigmoid resection for uncomplicated diverticulitis. *Dis Colon Rectum* 2003;46:385-8.
44. van de Wall BJM, Stam MAW, Draaisma WA, et al. Surgery versus conservative management for recurrent and ongoing left-sided diverticulitis (DIRECT trial): an open-label, multicentre, randomised controlled trial. *Lancet Gastroenterol Hepatol* 2017;2:13-22.
45. Feingold D, Steele SR, Lee S, et al. Practice parameters for the treatment of sigmoid diverticulitis. *Dis Colon Rectum* 2014;57:284-94.
46. Salem L, Veenstra DL, Sullivan SD, Flum DR. The timing of elective colectomy in diverticulitis: a decision analysis. *J Am Coll Surg* 2004;199:904-12.
47. Biondo S, Borao JL, Kreisler E, et al. Recurrence and virulence of colonic diverticulitis in immunocompromised patients. *Am J Surg* 2012;204:172-9.
48. Hjern F, Josephson T, Altman D, Holmström B, Johansson C. Outcome of younger patients with acute diverticulitis. *Br J Surg* 2008;95:758-64.
49. Klarenbeek BR, Samuels M, van der Wal MA, van der Peet DL, Meijerink WJ, Cuesta MA. Indications for elective sigmoid resection in diverticular disease. *Ann Surg* 2010;251:670-4.
50. Abraha I, Binda GA, Montedori A, Arezzo A, Cirocchi R. Laparoscopic versus open resection for sigmoid diverticulitis. *Cochrane Database Syst Rev* 2017;11:CD009277.
51. Schwenk W, Haase O, Neudecker J, Müller JM. Short term benefits for laparoscopic colorectal resection. *Cochrane Database Syst Rev* 2005;3:CD003145.
52. Bianchi M, Festa V, Moretti A, et al. Meta-analysis: long-term therapy with rifaximin in the management of uncomplicated diverticular disease. *Aliment Pharmacol Ther* 2011;33:902-10.
53. Stollman N, Magowan S, Shanahan F, Quigley EM. A randomized controlled study of mesalamine after acute diverticulitis: results of the DIVA trial. *J Clin Gastroenterol* 2013;47:621-9.
54. Carter F, Alsayb M, Marshall JK, Yuan Y. Mesalamine (5-ASA) for the prevention of recurrent diverticulitis. *Cochrane Database Syst Rev* 2017;10:CD009839.

Copyright © 2018 Massachusetts Medical Society.

SPECIALTIES AND TOPICS AT NEJM.ORG

Specialty pages at the *Journal's* website (NEJM.org) feature articles in cardiology, endocrinology, genetics, infectious disease, nephrology, pediatrics, and many other medical specialties.